

## Safety and Feasibility of Laparoscopic Surgery in the Management of Hepatic Hydatid Cysts: Long Term Results from an Endemic Area

Arshad Rashid, MS, FNB(MAS), FIAGES<sup>1</sup>; Ajaz Ahmad Wani, MS<sup>2</sup>;  
Asim Rafiq Laharwal, MS, FIAGES<sup>1</sup>

<sup>1</sup>Lecturer, Department of Surgery, Government Medical College & Associated Hospitals, Srinagar -190010.

<sup>2</sup>Surgeon Specialist, Health Services Kashmir - 190001. (Current Affiliation)

Post-graduate Scholar & Registrar, Department of General Surgery, GMC Srinagar – 190010. (At the time of study)

Corresponding Author: Dr Asim Rafiq Laharwal

---

**Abstract: Background:** Traditionally open surgical techniques have been used for the management of hepatic hydatid disease. The aim of our study was to evaluate the feasibility of laparoscopic surgery and its safety in its management with special reference to perioperative and postoperative complications and cyst recurrence.

**Methods:** Ours was a prospective cohort study of 136 patients of hepatic hydatid disease managed by laparoscopy over a period of 6 years with a minimum follow-up of 5 years conducted in a tertiary care hospital of an endemic area.

**Results:** The mean operative time was 86 minutes. We encountered spillage in 16 patients with one patient developing anaphylaxis. We needed conversion in one patient. Biliary leaks occurred in 13 patients with two eventually needing endoscopic sphincterotomy. One patient developed infection in the residual cavity and one patient had a recurrence.

**Conclusion:** Laparoscopic management is a feasible and safe approach but should be used in carefully selected patients.

**Key Words:** Hydatid cyst; Laparoscopy; Liver; Echinococcus; Recurrence.

---

Date of Submission: 20-03-2019

Date of acceptance: 06-04-2019

---

### I. Introduction

Hydatid disease of the liver has been known since ancient times. Hippocrates, who speaks of it as “liver full of waters”, knew hydatid disease [1-3]. The first case of hydatid disease was observed in North America in 1808 [4]. The disease has a worldwide distribution and is most commonly seen in sheep rearing areas of the world. The management of hepatic hydatid disease (HHD) is essentially surgical and is complemented by medical therapy (anti-helminthic medication) [5-10]. The surgical treatment can be conservative or radical.

Traditionally open surgical techniques have been used for HHD [11-14]. With the explosion of laparoscopic surgery many surgeons tried for laparoscopic intervention which had results comparable to those of open surgery with added benefits of reduced incision related morbidity, pain, hospital stay and time away from productive activities [12]. However most are still not convinced about the role of laparoscopy in HHD owing to the fear of difficulty in controlling spillage and higher complication and recurrence rates [3-16]. The aim of our study was to evaluate the feasibility of laparoscopic surgery and its safety in HHD with special reference to perioperative and postoperative complications and cyst recurrence.

### II. Material And Methods:

Ours was a prospective cohort study conducted in the Department of Surgery, Government Medical College, Srinagar from July 2007 to July 2013 and was performed on documented (on ultrasonography and computed tomography) cases of HHD who were subjected to laparoscopic hydatid cystectomy. Patients of all ages and both sexes were taken. Intra-parenchymal cysts, more than three cysts, Gharbi type 5 cysts and posteriorly located cysts were excluded from the study. A detailed history was taken; examination and relevant investigations were done. Peri-operative albendazole (10mg/kg) was given to all patients. All the patients and their attendants were explained the procedure in detail and an informed consent was taken for the same. A clearance from institutional ethical committee was obtained for the study.

All the patients were operated under general anaesthesia; ports were placed according to the location of

the cyst. The cysts were identified and adhesions if any were separated. Palanivelu hydatid system (PHS) was used for puncture and aspiration of the cyst, once the fluid laminating membrane and daughter cysts were aspirated the interior of the cyst cavity was visualized for any cysto-biliary communication; and any communication found was under-run in a figure-of-eight manner by absorbable sutures. The residual cavity was managed by external tube drainage and omentoplasty. Various intraoperative and postoperative parameters like conversion to open, any intraoperative complications, postoperative pain, bile leak, hospital stay, time to return to daily life activities were evaluated. Postoperative pain was measured by visual analog scale. The pain scores were obtained at 1, 2, 4, 6, 8, 12, 24, 36, 48, and 72 hours postoperatively. Analgesics were administered if the visual analog pain score was  $>6$ .

All the patients were followed-up for minimum five years. Protocol for follow-up included a detailed clinical examination and an abdominal ultrasonogram with a 3.5 MHz convex sector transducer probe, performed in the standard manner, to rule out any recurrence or collection. This was done every fortnightly for the first two months, then two-monthly for next ten months and thereafter six-monthly for the next four years. A Contrast Enhanced Computed Tomography (CECT) of the abdomen confirmed recurrence or collection, if any. Any patient not meeting these follow-up criteria was excluded from the study. The data thus collected was compiled and analyzed using SPSS version 21 for Mac (IBM Corporation, 2012). Qualitative variables were expressed as proportions in percentages.

### **III. Results**

The study consisted of 136 patients who were subjected to laparoscopic hydatid cystectomy by using PHS. External tube drainage was done in all the patients however; omentoplasty in addition was done in 15 (11%) patients to obliterate large cavities. The baseline parameters are given in Table 1. One (0.7%) patient was converted to open; reason being dense adhesions obstructing the operative field. Spillage occurred in 16 patients (11.5%) and one patient (0.7%) developed anaphylaxis. The mean operative time was  $86 \pm 14.67$  minutes. The mean visual analog score for pain on the first postoperative day was  $3.45 \pm 0.132$ . On the second postoperative day, the mean pain score observed was  $2.81 \pm 0.307$ . On the third postoperative day, the mean pain score was  $1.76 \pm 0.287$ . Cysto-biliary communication was noted in nine patients (6.6%) intra-operatively and was managed by a figure of eight suture. Biliary leak occurred in 13 (9.5%) patients. Bile leak persisted for a mean duration of  $17.6 \pm 2.7$  days and was managed conservatively except in two (1.4%) who required an Endoscopic Retrograde Cholangiography with Endoscopic Sphincterotomy. The hospital stay ranged from 3 days to 9 days with an average of  $5.1 \pm 2.2$  days. Time to return to work ranged from 8 days to 16 days with a mean of  $13.4 \pm 1.6$  days. One (0.7%) of our patients developed infection of the residual cavity 4 weeks after surgery. Diagnosis was established on an abdominalsonogram and was confirmed by CECT abdomen. Percutaneous drainage was done under ultrasonic guidance and patient went home without any further sequel. In our study one (0.7%) recurrence was noted in a patient after a period of 11 months, which was then managed by open surgery.

### **IV. Discussion**

Hydatid disease is a zoonotic infection caused by adult or larval stages of the tapeworm of genus *Echinococcus*. Carnivores like dogs act as definitive hosts and harbor the adult worm whereas sheep and other herbivores are intermediate hosts. Humans are the accidental intermediate hosts [1-6]. Once within the man or other intermediate host the ingested eggs hatch in the duodenum to release the true larvae (oncospheres) that penetrate the mucosa of small intestine and enter the portal circulation. Liver acts as the first effective filter for most of the larvae and therefore is the most common site of involvement [7-13]. In this prospective study we operated upon 130 patients of HHD to see the feasibility and safety of laparoscopy. Laparoscopy as such does not compromise the four basic rules of treating hydatid cysts that is complete sterilization of the cyst with scolicidal agent, total removal of lining membrane and daughter cysts, prevention of spillage, and management of the residual cavity [4-16].

In our study one patient (0.7%) was converted to open, the reason for conversion being multiple adhesions obscuring the operative field. This patient was previously operated for perforated duodenal ulcer by upper paramedian incision. Bickel A et al in their study noted a conversion rate of 3.22% [17]. Baskaran V et al had a conversion rate of 11% higher than the results of other studies, the reason may be the improper selection of patients as has been concluded by the author that both the conversion and complications can be reduced by the proper selection of patients vis-a-vis location of the cysts [18]. We probably had a lesser conversion rate owing to our experience in laparoscopy and proper selection of cases.

In our study spillage occurred in 16 (11.5%) patients, one of them developed anaphylaxis(0.7%). In all the patients the procedure was completed laparoscopically and anaphylaxis was managed with fluids, ephedrine and dopamine. Postoperative convalescence was uneventful in all the patients. Baskaran V et al had a spillage at the rate of 27.7% [18]. The lower rate of spillage reported by us is because we were using PHS, which is a closed system and minimizes spillage.

Though we identified cysto-biliary communication in nine (6.6%) patients and managed that by intracorporeal suturing, still biliary leak occurred in 13 (9.5%) patients, which is in accordance with Palanivelu C et al [19]. These patients started to drain bile in 1st week till 3 weeks, and then stopped of its own. The time to return to work in our study was 8 to 16 days, which is in accordance with the results of Ramachandran C S et al [6]. One (0.7%) patient in our study had recurrence, which was picked up at 11 months and was managed subsequently by open surgery. Our rates of recurrence are lower than reported elsewhere (3.66%) in literature [7]. One of the limitations of our study is that it only was a cohort study and did not involve matched controls managed by open surgery but this time we only wished to assess the feasibility of laparoscopy and its long-term results, so did not study matched open controls. The strength of our study is its long-term follow-up of five years and adherence to strong follow-up protocol.

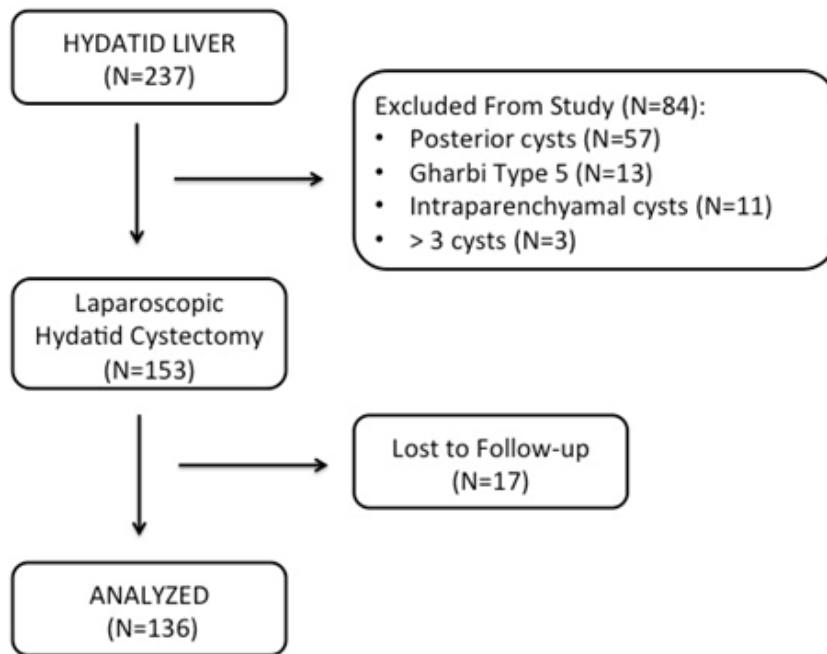
## V. Conclusion

Laparoscopic management of HHD is a feasible and safe alternative to open surgery and affords all the benefits of minimal access approach but should be used in carefully selected patients.

## References

- [1]. Rana UV, Sehgal S, Bhatia R, Bhardwaj M. Hydatidosis in animals in and around Delhi. *J Commun Dis.* 1986 Jun;18(2):116-9.
- [2]. Merrett N, Hunt DR. Recurrent hepatic hydatid disease or prior omentoplasty: diagnostic dilemma. *Aust N Z J Surg.* 1989 Oct;59(10):791-4.
- [3]. Reddy CR, Narasiah IL, Parvathi G, Rao MS. Epidemiology of hydatid disease in Kurnool. *Indian J Med Res.* 1968 Aug;56(8):1205-20.
- [4]. Akin ML, Erenoglu C, Uncu EU, Basekim C, Batkin A. Surgical management of hydatid disease of the liver: a military experience. *J R Army Med Corps.* 1998 Oct;144(3):139-43.
- [5]. Gourgiotis S, Stratopoulos C, Moustafellos P, Dimopoulos N, Papaxoinis G, Vougas V, et al. Surgical techniques and treatment for hepatic hydatid cysts. *Surg Today.* 2007;37(5):389-95.
- [6]. Wani AA, Rashid A, Laharwal AR, Kakroo SM, Abbas M, Chalkoo MA. External tube drainage or omentoplasty in the management of residual hepatic hydatid cyst cavity: a prospective randomized controlled study. *Ger Med Sci.* 2013;11:Doc11.
- [7]. Arikan S, Kocakusak A, Yucel AF, Daduk Y. Evaluation of tube drainage method in the treatment of hydatid cyst of liver. *Hepatogastroenterol.* 2007;54(74):470-4.
- [8]. Marinaç M, Brătucu E, Badarau A, Straja D, Boru CE, Stefan I, et al. External drainage of the hepatic post hydatid remnant cavity. *Chirurgia (Bucur).* 2009 Mar-Apr;104(2):151-7.
- [9]. Platell C, Cooper D, Papadimitriou JM, Hall JC. The omentum. *World J Gastroenterol.* 2006;6(2):169-76.
- [10]. Ozacmak ID, Ekiz F, Ozmen V, Isik A. Management of residual cavity after partial cystectomy for hepatic hydatidosis: comparison of omentoplasty with external drainage. *Eur J Surg.* 2000 Sep;166(9):696-9.
- [11]. Reza Mousavi S, Khoshnevis J, Kharazm P. Surgical treatment of hydatid cyst of the liver: drainage versus omentoplasty. *Ann Hepatol.* 2005 Oct-Dec;4(4):272-4.
- [12]. Rashid A, Nazir S, Kakroo SM, Chalkoo MA, Razvi SA, Wani AA. Laparoscopic interval appendectomy versus open interval appendectomy: a prospective randomized controlled trial. *Surg Laparosc Endosc Percutan Tech.* 2013 Feb;23(1):93-6.
- [13]. Muftuoglu MA, Koksall N, Topaloglu U. The role of omentoplasty in the surgical management of remnant cavity in hepatic hydatid cyst. *HPB (Oxford).* 2005;7(3):231-4.
- [14]. Utkan NZ, Cantürk NZ, Gönüllü N, Yildirim C, Dülger M. Surgical experience of hydatid disease of the liver: omentoplasty or capitonnage versus tube drainage. *Hepatogastroenterology.* 2001 Jan-Feb;48(37):203-7.
- [15]. Xynos E, Pechlivanides G, Tzortzinis A, Papageorgiou A, Vassilakis JS. Hydatid disease of the liver. Diagnosis and surgical treatment. *HPB Surg.* 1991 May;4(1):59-66; discussion 66-7.
- [16]. Mushtaque M, Mir MF, Malik AA, Arif SH, Khanday SA, Dar RA. Atypical localizations of hydatid disease: Experience from a single institute. *Niger J Surg.* 2012;18(1):2-7.
- [17]. Mentis A, Yüzer Y, Ozbal O, Coker A, Ilter T, Musoğlu A. Omentoplasty versus introflexion for hydatid liver cysts. *J R Coll Surg Edinb.* 1993 Apr;38(2):82-5.
- [18]. Kama NA, Sahin M, Göçmen E, Bayrak M, Kulaçoğlu H, Akat AZ. The results of surgical techniques in hepatic hydatidosis: treatment with drainage versus treatment without drainage--a 6-year experience. *J R Coll Surg Edinb.* 1998 Aug;43(4):254-6.
- [19]. Bilge A, Sözüer EM. Diagnosis and surgical treatment of hepatic hydatid disease. *HPB Surg.* 1994;8(2):77-81.

**Figure 1: CONSORT Flow Diagram of the study**



**Table 1: Baseline parameters of the cases (N=136)**

Age	38 ± 4.2 years
Sex (M:F)	1.3:1
Rural:Urban	8:1
Cyst in Right lobe	107 (78.67%)
Cyst in Left lobe	21 (15.44%)
Multiple cysts	8 (5.89%)

Dr Asim Rafiq Laharwal" Safety and Feasibility of Laparoscopic Surgery in the Management of Hepatic Hydatid Cysts: Long Term Results from an Endemic Area" IOSR Journal of Dental and Medical Sciences (IOSR-JDMS), vol. 18, no. 4, 2019, 14-17.